



# Aural irrigation using the OtoClear<sup>®</sup> Safe Irrigation System in children

Ellen M. Mandel\*, Joseph E. Dohar, Margaretha L. Casselbrant

Department of Pediatric Otolaryngology, Children's Hospital of Pittsburgh and the Department of Otolaryngology, University of Pittsburgh School of Medicine, 3705 Fifth Ave., Pittsburgh, PA 15213, USA

Received 11 December 2003; received in revised form 23 April 2004; accepted 27 April 2004

## KEYWORDS

Cerumen;  
Irrigation;  
Earwax;  
Ear canal

## Summary

**Objective:** To evaluate the safety and efficacy of the OtoClear<sup>®</sup> Safe Irrigation System for removing cerumen from the external auditory canal in children.

**Methods:** Eligible subjects were 6 months–17 years of age with cerumen obstructing  $\geq 50\%$  of the tympanic membrane (TM) from view (by otoscopy). Pneumatic otoscopy, tympanometry, and audiometry were performed followed by cleansing of the affected ear canal(s) with the OtoClear<sup>®</sup> Safe Irrigation System and warm tap water. Otoscopy was performed after each wash of the canal. A curette or small alligator forceps was used to remove remaining cerumen if necessary. Tympanometry and audiometry were repeated after all procedures were completed. Telephone contact was made 1 week later regarding symptoms of acute otitis externa or any other problems.

**Results:** Eighteen children (28 ears) ages 1–10/12 to 11–2/12 years were entered. Four had previously had tympanostomy tubes. At entry, there was no visible TM in 19 ears, 5–10% visible TM in 5 ears, 20% in 1 ear, and 30–40% of the TM in 3 ears. The number of washes needed per ear was: 1 wash—16 ears, 2 washes—8 ears, 3 washes—1 ear, 4 washes—2 ears; washing was stopped in 1 ear because of pain. After irrigation, a curette or forceps was used in 6 ears. Following the procedures,  $\geq 95\%$  of the TM was visible in 24 ears, and  $\geq 80\%$  was visible in all ears. Six ears (4 children) with flat tympanograms at entry became normal after irrigation. On audiometry, a conductive loss in 2 ears at entry resolved after irrigation. The mean change in pure tone average (PTA) was  $-2.9$  dB. Three subjects were noted to have hearing losses  $> 5$  dB at some frequencies which on review by audiologists were deemed non-significant. No perforations of the TM occurred. There were no reports of otitis externa or any other adverse events occurring after leaving the clinic.

**Conclusion:** We found the OtoClear<sup>®</sup> Safe Irrigation System to be safe and effective in our small sample of children. It was well tolerated in most and provided a non-traumatic method for the removal of obstructing cerumen.

© 2004 Elsevier Ireland Ltd. All rights reserved.

\* Corresponding author. Tel.: +1 412 692 6214; fax: +1 412 692 6074.

E-mail address: mandele@pitt.edu (E.M. Mandel).

## 1. Introduction

Though some cerumen is necessary for the maintenance of normal physiologic homeostasis within the lateral auditory canal, excessive accumulation leads to a pathological condition known as cerumen impaction. Cerumen, or too much of it, is a problem in pediatrics for several reasons. Physicians must often remove cerumen in children's ears to examine a febrile child or one complaining of ear pain or pulling at their ears. Lack of visibility of the tympanic membrane (TM) may prevent accurate diagnosis of middle-ear disease as well as problems of the external canal; cerumen accumulation has also been linked to chronic cough secondary to stimulation of Arnold's nerve, a branch of the vagus nerve [1]. Decreased hearing, a common pediatric complaint, can be the result of mechanical blockage of the canal as well as middle-ear disease, and for some, removal of the obstructing wax plug may be curative. Watkins et al. [2] reported that among 2959 schoolchildren in Dallas, Texas who failed pure tone audiological screening, 137 (4.63%) failed because of cerumen in the canal. For audiologists, cerumen management becomes a very common problem, as use of hearing aids may obstruct the normal extrusion of cerumen from the external canal [3] in addition to preventing accurate audiological testing. Long-standing cerumen impaction may encourage proliferation of bacterial and fungal pathogens that, in turn, result in low-grade otitis externa. Certain populations are known to be particularly prone to cerumen impaction, such as children with Down syndrome [4], as well as others with mental retardation, and the geriatric population [5].

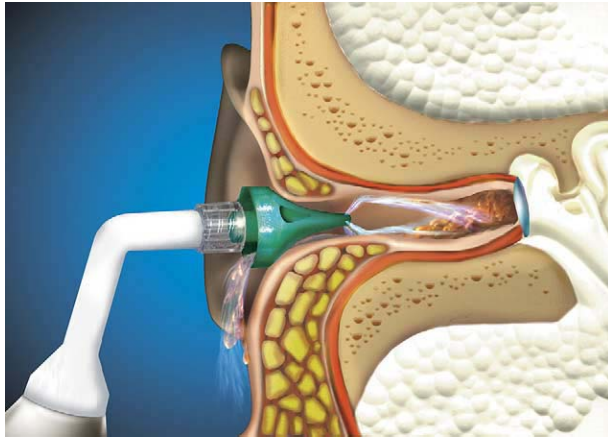
Several techniques have been used to remove cerumen from the external auditory canal. Cerumen can be removed mechanically under visualization by means of a curette or wire loop. Various substances have been used to try to soften the cerumen prior to removal. Oil-based organic solutions, such as olive oil, glycerin, and propylene glycol lubricate the plug and facilitate its mechanical removal. Aqueous solutions, such as water, 10% bicarbonate, 3% hydrogen peroxide, and 2% acetic acid, expand and loosen or dissolve the cerumen plugs [6]. Irrigation devices, such as an ear syringe, or Water Pik dental device [7] have also been widely used by practitioners. However, unlike devices which aim the stream of irrigation fluid at the TM, the OtoClear<sup>®</sup> Safe Irrigation Tip (Bionix, Toledo, Ohio) directs the water stream to the canal wall. This non-comparative, descriptive study was designed to evaluate the safety and efficacy of the OtoClear<sup>®</sup> Safe Irrigation System

for removing cerumen from the external auditory canal in children.

## 2. Methods

This study was performed at the ENT Research Center at Children's Hospital of Pittsburgh (CHP) and was approved by the Human Rights Committee of this institution. Subjects were eligible for entry if they were between 6 months and 17 years of age with cerumen in the external canal obstructing at least 50% of the tympanic membrane (TM) from view, as estimated on otoscopy. Children were excluded for: stenotic or atretic ear canals; known or suspected otitis externa or acute otitis media; TM perforation; tympanostomy tube present in the TM; history of prior otologic surgery other than tube insertion; history of trauma to the ear; known sensorineural hearing loss; neoplastic or inflammatory disorders of the ear; eczema or other inflammatory disorders of the skin; life threatening illnesses; known immune deficiency; and use of ear drops within 1 week of entry.

Children were recruited from patients followed in the ENT Research Center or the ENT clinic at CHP and from referrals from outside clinics or physicians. If the patient qualified and informed consent was obtained, the subject underwent pneumatic otoscopy, tympanometry, and audiometry. The subject then underwent irrigation of the affected ear canal(s) using the OtoClear<sup>®</sup> Safe Irrigation Tip attached to a Krups BioCare Irrigation unit. The irrigation tip is made of disposable medical grade plastic polymer with a central channel and three angled exit ports at the distal tip to allow water to exit the irrigation tip in three streams aimed at the canal walls rather than impacting the eardrum directly (Fig. 1). The tip also has continuous fluid exit passages to allow the effluent and debris to escape without pressure build-up. The BioCare base is a rechargeable portable device with a 205 ml water reservoir that supplies the irrigation fluid (tap water warm to the touch). The child was seated on an examining table or on a parent's lap and a plastic cape was applied to protect the child's clothes from the water. A small plastic basin (an emesis basin was used) was held underneath the child's ear, the irrigation tip was gently inserted into the child's ear and the device was then activated. The base was gently rotated back and forth while the tip was in the ear to facilitate cerumen removal. The device was turned off when the reservoir was empty; this was considered "one wash".



**Fig. 1** Illustration of OtoClear® Tip attached to irrigation device, showing the streams of irrigation fluid directed at the canal walls rather than the tympanic membrane (courtesy of Bionix Development Corporation).

After otoscopic inspection of the ear canal, the procedure was either repeated or not, depending on the visibility of the tympanic membrane. If a large piece of cerumen had been dislodged and was blocking the entrance to the external canal, it was removed manually with forceps or curette rather than repeating the irrigation. Tympanometry and audiometry were repeated after all procedures were completed. Telephone contact was made 1 week after the procedure to inquire about symptoms of acute otitis externa or any other problems after the irrigation.

Tympanograms were performed using a GSI-33 middle ear analyzer (Grason-Stadler Inc., Milford, NH). The test included an estimate of the acoustic equivalent volume of the external ear canal and a tympanogram from which estimates of peak compensated static acoustic admittance, tympanometric width and tympanometric peak pressure were determined. Audiometric procedures varied as a function of the age of the child. For children 5 years and older, air-conduction pure-tone thresholds for each ear at 0.5, 1, 2, and 4 kHz were obtained using conventional audiometric methods. Bone-conduction testing was done when air-conduction thresholds exceeded 15 dB HL. For children 30–59 months of age, play audiometry was used to obtain pure tone thresholds in each ear. The threshold-estimating protocol and criterion for bone conduction were the same as that used for older children. For younger children, visual reinforcement audiometry with a unilateral head turn, as described by Wilson and Thompson [8], was used to obtain sound field minimum response levels. Stimuli were speech and warble tones at audiometric test frequencies of 500–4000 Hz.

### 3. Results

Eighteen children (28 ears) ages 1–10/12 to 11–12 years were entered. Only 1 child was less than 3 years of age; a total of 8 children were less than 6 years old. Twelve were male, 11 were Caucasian, and 7 were African-American. Four had previously had tympanostomy tubes and 6 had been swimming in the week prior to entry. By otoscopy at entry, there was no visible TM in 19 ears, 5–10% visible TM in 5 ears, 20% in 1 ear, and approximately 30–40% of the TM was visible in 3 ears. The distribution of number of washes needed per ear was 1 wash—16 ears, 2 washes—8 ears, 3 washes—1 ear, 4 washes—2 ears; washing could not be completed in 1 ear because of pain. No more than four washes were performed on any one ear because of erythema and irritation of the canal (one child) or by the subject's request (one child). After irrigation, a curette or forceps was used in six ears to remove a large wax plug from the entrance to the canal (three ears) or to remove a piece of residual wax from farther down the canal (three ears). By the end of the procedures,  $\geq 95\%$  of the TM was visible in 24 ears, and  $\geq 80\%$  of the TM was visible in all ears. In six ears (four children) tympanograms were flat at entry and became normal after irrigation. On audiometry, two ears with a conductive loss at entry had resolution of the conductive loss after cleaning of the canal. Mean change in hearing thresholds between entry and end of procedures in the 27 ears on which ear-specific thresholds could be obtained are shown in the Table 1. In three (16.7%) of the 18 subjects hearing was noted to be poorer by greater than 5 dB at one or two frequencies after cerumen removal at various frequencies: one subject at 2000 Hz (10 dB), one at 1000 (20 dB) and 4000 Hz (15 dB), and one at 500 (15 dB) and 4000 Hz (10 dB). On review of the audiograms by an audiologist these were deemed non-significant. Possible causes were test-retest inconsistency, residual water in the canal, and the inherent limitations in testing children just after a procedure. No perforations of the TM occurred

**Table 1** Change in hearing after cerumen removal ( $N = 27$  ears)

Measure (Hz)	Mean (dB)	Range (dB)
500	-3.15	-15, +15
1000	-2.60	-20, +20
2000	-3.00	-25, +10
4000	-1.65	-25, +15
PTA*	-2.90	-16.7, +8.3

Note: Negative value indicates lower hearing level, i.e., improvement. Hz: Hertz; dB: decibels; PTA: pure tone average.  
\* PTA: average of values at 500, 1000, and 2000 Hz.

during the study. Two children, one with a history of motion sickness, complained of dizziness immediately after canal irrigation but did not have nystagmus; the dizziness resolved in minutes. Another child had undiagnosed otitis externa behind the impacted cerumen and cried with pain immediately at the start of the irrigation. No children were diagnosed with otitis media. Follow-up information was obtained on nine subjects; there were no reports of otitis externa or any other adverse events occurring after irrigation.

#### 4. Discussion

We found aural irrigation with the OtoClear<sup>®</sup> Safe Irrigation System to be safe and effective in the small group of 18 children in our study. However, to truly determine safety, a larger number of subjects would be needed. The OtoClear<sup>®</sup> Tip, utilizing three jets of water aimed at the canal walls rather than at the TM, was well tolerated in most subjects in our study and provided a non-traumatic method for the removal of obstructing cerumen. This may be particularly useful in screaming, squirming children in whom removal of cerumen by curette would likely traumatize the canal or possibly perforate the TM. It should be re-emphasized that irrigation as a tool to remove wax in the ear canal is contraindicated in a non-intact TM. Prior to irrigation, it should always be determined that the TM is intact. In a child with a past history of otorrhea or tympanostomy tubes, an examination subsequently documenting an intact TM should be sought in the medical records. In children without complete occlusion of the canal by cerumen, mobility on pneumatic otoscopy or a small canal volume on tympanometry would provide evidence of an intact TM.

In addition to allowing inspection and evaluation of the tympanic membrane, improvement in mean hearing levels at all frequencies was noted. Sharp et al. [9] reported a mean improvement in hearing in 20 outpatients (age not specified but presumably adults) of 5 dB after removal of occlusive cerumen. Memel et al. [10] reported the results of their single-blind randomized trial in adults (mean age 63 years) of hearing testing before and after ear syringing versus twice before ear syringing. They found an improvement in the 4-frequency PTA of 10 dB or more in 34% of the intervention group compared to 1.6% of the control group; for those whose improvement was greater than 10 dB, the improvement ranged from 15 to 36 dB with a mean of 24 dB. In the intervention group, 39 (74%) of 53 patients had their ear syringed specifically for

complaints of decreased hearing. In our series, mean pure-tone thresholds improved at all frequencies but mean improvement was less than 5 dB which is within the range of test-retest fluctuation. Audiology was obtained in our study to document a lack of harm rather than as a measure of benefit but we did note that in two ears (one subject) a conductive loss present prior to irrigation was no longer present after the procedure. Also, in our patient group, cerumen had to be blocking visibility of at least 50% of the TM and total occlusion of the canal was not required; total occlusion would, presumably, be associated with greater loss of hearing.

We did not use any ceruminolytic substances prior to irrigation as recommended by some [3,11]. In spite of this, we were able to produce good visibility of the TM ( $\geq 80\%$ ) in all ears. Use of ceruminolytics prior to irrigation may have allowed us to use fewer "washes" of the canal and therefore less time or produced better results, i.e., more than 80% visibility of the TM but another study would be needed to ascertain this.

#### Acknowledgments

Supported by a grant from the Bionix Development Corporation, Toledo, OH.

We thank the following colleagues who contributed expertise to this project: Kathleen Tekely, RN, MN; Susan Strelinski; Gretchen Probst, MA; Marcia Kurs-Lasky, MS.

#### References

- [1] F. Jegoux, F. Legent, C. Beauvillain de Montreuil, Chronic cough and ear wax, *Lancet* 360 (2002) 618.
- [2] S. Watkins, T.H. Moore, J. Phillips, Clearing impacted ears, *Am. J. Nurs.* 84 (1984) 1107.
- [3] B.B. Ballachanda, C.J. Peers, Cerumen management, *ASHA* 34 (1992) 43–46.
- [4] A.J. Dahle, F.P. McCollister, Hearing and otologic disorders in children with Down syndrome, *Am. J. Ment. Defic.* 90 (1986) 636–642.
- [5] R.J. Roeser, B.B. Ballachanda, Physiology, pathophysiology, and anthropology/epidemiology of human earcanal secretions, *J. Am. Acad. Audiol.* 8 (1997) 391–400.
- [6] M. Hawke, Update on cerumen and ceruminolytics., *Ear Nose Throat J.* 81 (suppl. 1) (2002) 23–24.
- [7] G. Larsen, Removing cerumen, *Am. J. Nurs.* 76 (1976) 264–265.
- [8] W.R. Wilson, G. Thompson, Behavioral audiometry, in: J. Jerger (Ed.), *Pediatric Audiology*, College Hill, San Diego, CA, 1984, pp. 1–44.

- [9] J.F. Sharp, J.A. Wilson, L. Ross, R.M. Barr-Hamilton, Ear wax removal: a survey of current practice, *BMJ* 301 (1990) 1251–1253.
- [10] D. Memel, C. Langley, C. Watkins, B. Laue, M. Birchall, M. Bachmann, Effectiveness of ear syringing in general practice: a randomized controlled trial and patients' experiences, *Br. J. Gen. Pract.* 52 (2002) 906–911.
- [11] S.A. Wilson, R. Lopez, What is the best treatment for impacted cerumen? *J. Fam. Pract.* 51 (2002) 117.

Available online at [www.sciencedirect.com](http://www.sciencedirect.com)

